



Acute anterior hypopyon uveitis after non-penetrating ocular trauma in a patient with ankylosing spondylitis and HLA-B27 positivity

Lucas A. Garza Garza, Eugenia M. Ramos-Davila, Raul E. Ruiz-Lozano, Gustavo Ortiz Morales, Carlos Alvarez-Guzman, Alejandro Rodriguez-Garcia

Tecnologico de Monterrey, Escuela de Medicina y Ciencias de la Salud, Mexico

ABSTRACT

Acute anterior uveitis is the most common type of uveitis. Subsequent reactivation of acute anterior uveitis after the successful control of an initial episode has been linked to several risk factors. Less commonly, acute anterior uveitis reactivation has been associated with a traumatic stimulus. We present the case of a 55-year-old man with a 2-year history of neck and low-back pain and morning stiffness and a family history of rheumatoid arthritis. He presented to the outpatient clinic complaining of blurry vision in his left eye after a nonpenetrating trauma with a frosted glass splinter. A corneal leucoma corresponding to the trauma and an acute anterior uveitis with a hypopyon was found in his

left eye. Further rheumatological evaluation yielded a diagnosis of HLA-B27 positive ankylosing spondylitis. The acute anterior uveitis resolved without complications with topical steroids and cycloplegics. The present case and others previously reported suggest that ocular trauma could be a trigger of AAU in predisposed patients. Furthermore, a systemic evaluation should be considered in patients with ocular inflammation out of proportion to a traumatic stimulus and who present systemic symptoms compatible with diseases known to cause ocular inflammation.

KEY WORDS: HLA-B27, ocular trauma, acute anterior uveitis, ankylosing spondylitis.

INTRODUCTION

Acute anterior uveitis (AAU) is the most frequent uveitis presentation, and almost 50% of the cases are associated with the HLA-B27 haplotype in the context of a seronegative spondyloarthropathy (SpA), mainly undetermined disease (peripheral SpA and non-radiographic axial SpA) and ankylosing spondylitis [1, 2]. Patients with HLA-B27 associated AAU usually complain of unilateral sudden ocular pain, redness, blurred vision, and photophobia [1]. Anterior chamber cells, flare, and keratic precipitates (KPs) are typical signs observed under the slit-lamp [2]. HLA-B27 AAU is a stereotyped disease characterized by alternating bilateral recurrent attacks of intraocular inflammation with a prominent anterior chamber protein exudation and hypopyon formation [1, 2]. In contrast, simultaneous bilateral AAU is more frequent in HLA-B27 negative patients [1]. Despite this stereotyped presentation pattern, there is no pathognomonic feature of HLA-B27 AAU [2]. The pathogenesis of HLA-B27 AAU is unclear [2]. Moreover, the mechanisms triggering recurrent episodes of AAU after achieving initial remission are also unknown. Chan *et al.* [3] reported that back pain and

stiffness at diagnosis, and the presence of complications during the presenting episode of uveitis such as cystoid macular edema, ocular hypertension, and cataract, were associated with a higher risk of recurrent episodes. Few authors have reported the occurrence of AAU in patients with ankylosing spondylitis or HLA-B27 positivity after ocular trauma [4, 5] and after chelation therapy with ethylenediaminetetraacetic acid (EDTA) for the management of band keratopathy [6]. We report a case of an HLA-B27 positive male patient who presented with AAU and hypopyon after a non-penetrating ocular trauma with a frosted glass splinter.

CASE REPORT

Informed consent was obtained from the patient for the evaluation and publication of the case report. A 55-year-old man presented to our outpatient ophthalmology clinic complaining of blurry vision in his left eye (OS) after experiencing a blunt ocular trauma with a frosted glass splinter 7 days before consultation. The patient had a family history of rheumatoid arthritis in his mother. He also reported having a two-year history of pain and morning stiffness in his

CORRESPONDING AUTHOR

Prof. Alejandro Rodriguez-García, Tecnológico de Monterrey, Escuela de Medicina y Ciencias de la Salud, Mexico, e-mail: immuneye@gmail.com

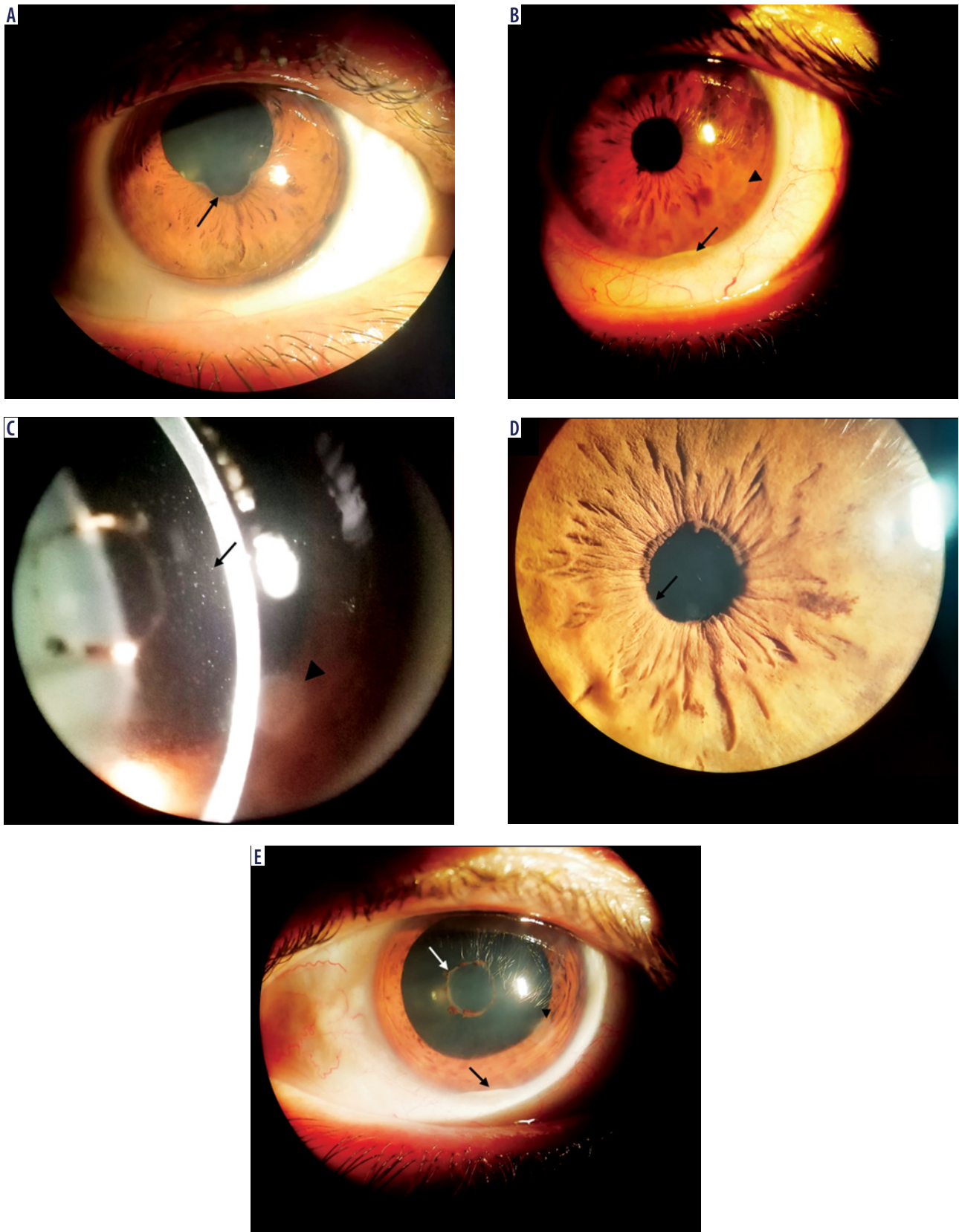


Figure 1. Clinical photographs of the right eye (A) and left eye (B–E). Posterior iris synechiae were visible inferiorly in the right eye (A, black arrow), with no active inflammation. On the left eye, a small corneal leucoma corresponding to the non-penetrating ocular trauma was observed (B, C, E, arrowhead), along with an inferior hypopyon (B, E, black arrow) and marked cellularity (C, black arrow). Finally, posterior iris synechiae were visible inferiorly (D, black arrow) and underwent lysis after pharmacological mydriasis (E, white arrow)

neck and lower back that improved throughout the day. He denied any previous episodes of red eye, pain, or blurry vision. His best-corrected visual acuity was 20/20 in both eyes (OU). The slit-lamp examination revealed a corectopic pupil and posterior iris synechiae inferiorly (Figure 1A) with no active inflammation in the right eye (OD). The left eye showed ciliary injection, a 1 × 1 mm corneal leucoma, fine KPs, and a hypopyon (Figure 1B). The corneal leucoma was visualized as a subepithelial haze covered by an intact epithelium. Fluorescein dye was instilled in the OS and revealed neither an epithelial defect nor an aqueous leak. No corneal infiltration suggestive of an infectious keratitis was found during slit lamp examination. Anterior chamber cells (2+), flare, and posterior iris synechiae were also observed OS (Figure 1C, D). Pharmacological mydriasis with phenylephrine-tropicamide eyedrops induced total synechiolysis OS (Figure 1E). The posterior segment was normal OU. No focal lens opacities or retinal lesions suggestive of a penetrating trauma were found OS. Topical therapy with 1% prednisolone acetate every hour and 1% atropine QID was initiated OS. Suspecting HLA-B27 associated uveitis and ankylosing spondylitis, a C-reactive protein (CRP), erythrocyte sedimentation rate (ESR), complete blood count (CBC), FTA-ABS, and HLA-B27 tests, and referral to the rheumatology service were requested. The CRP (96.2 UI/ml) and ESR (98 mm/h) were elevated, and the HLA-B27 haplotype was positive, and further rheumatological evaluation yielded a diagnosis of ankylosing spondylitis. Additionally, hepatitis B and C, HIV, and tuberculosis testing with purified protein derivative were ordered for potential initiation of anti-tumor necrosis factor- α (TNF- α) biologic therapy. Four days after, the hypopyon disappeared, and topical corticosteroids were slowly tapered. The cells and flare disappeared completely OS, no further complications developed, and vision remained 20/20 OU. Systemic treatment with daily sulfasalazine 2.5 g and celecoxib 200 mg BID PO was administered. After three months, the patient remains in vigilance with no further AAU flare-ups.

DISCUSSION

Proinflammatory cytokines, including TNF- α , gamma-interferon (INF- γ), and interleukins (IL)-2, -12, and -17, are overexpressed in the aqueous humor of AAU patients [2]. These cytokines induce reactive oxygen species that break down the blood-ocular barrier and promote angiogenesis, which in turn release more inflammatory molecules, producing a positive feedback loop perpetuating ocular inflammation [7, 8]. Since non-penetrating ocular trauma or surgery can induce inflammation, trauma could serve as a triggering mechanism for this feedback loop [5, 6, 8, 9]. In the present case, whether non-penetrating trauma elicited an inflammatory response in the eye or other mechanisms were the inciter for active inflammation is unknown. Evidence of previous inflammation (a corectopic pupil and posterior synechiae) were present in the contralateral eye. While the patient denied any past symptom-

atology in the OD, previous evident inflammatory episodes could have resolved spontaneously, considering that alternating attacks of intraocular inflammation are common in HLA-B27 related AAU [1]. As pointed out by other authors [5], it is also possible that the ocular trauma merely brought attention to an already active condition. Nonetheless, as cases of reactivation of AAU with traumatic stimuli [4-6] in HLA-B27 positive patients have been previously reported, a relationship between trauma and reactivation is a possibility in this patient. After an exhaustive literature search, we only found five HLA-B27 episodes of AAU after non-penetrating ocular trauma [4-6]. Rosenbaum *et al.* [5] reported an 18-year-old male patient who experienced AAU with hypopyon after a mild ocular trauma with a blunt object that resolved entirely with topical and oral steroids. Babu *et al.* [6] reported a 70-year-old male patient who experienced AAU with hypopyon first OD and then OS, each after EDTA chelation therapy for band keratopathy. Both episodes resolved with topical prednisolone acetate, topical cycloplegics, and oral steroids [6]. Finally, Seymour *et al.* [4] reported the last two eyes with recurrent inflammation after trauma, but no specific clinical data are available for these cases. The fact that all eyes with available data presented with hypopyon could suggest that AAU reactivated by ocular trauma in HLA-B27 positive patients presents more commonly with hypopyon, as the prevalence of hypopyon in non-traumatic HLA-B27 related AAU attacks is only 8.6-15% [10]. Nonetheless, not enough cases exist for an adequate comparison. Previous authors have reported risk factors for recurrence of AAU. Chan *et al.* [3] found that back pain and stiffness at diagnosis and the presence of complications during the presenting episode of uveitis conferred a higher risk of AAU reactivation (odds ratios 2.29 and 3.86, respectively). Neti *et al.* examined patients with recurrent AAU using questionnaires and found that those with a higher Srithanya Stress Test score and less than seven hours of sleep time had higher chances of recurrences (odds ratio 9.07 and 12.12 respectively) [11]. None of the patients reported eye trauma before AAU reactivation [11]. The present case and those previously reported [4-6] suggest that trauma may also be a risk factor for the initiation of an AAU episode in HLA-B27 positive patients. Nonetheless, more extensive analytic studies are needed to test this hypothesis.

In conclusion, ocular trauma could be a trigger of AAU in predisposed patients, and these episodes may present more commonly with hypopyon. As only case reports and short series exist, longitudinal and analytic studies are needed to evaluate the possibility of AAU reactivation associated with trauma and its characteristics and outcomes.

A question remains if every patient with a family history of rheumatic disease complaining of early morning lower back pain and stiffness in the context of acute iritis after blunt ocular trauma should always have a thorough rheumatic evaluation, including an HLA-B27 haplotype test. We suggest that it should, if the inflammatory episode is ante-

rior, unilateral, and recurrent, particularly if it is accompanied by a severe anterior chamber reaction characterized by extensive fibrin exudation, plasmoid body formation, or hypopyon.

DISCLOSURE

The authors declare no conflict of interest.

References

1. D'Ambrosio EM, La Cava M, Tortorella P, et al. Clinical features and complications of the HLA-B27-associated acute anterior uveitis: a metanalysis. *Semin Ophthalmol* 2017; 32: 689-701.
2. Wakefield D, Yates W, Amjadi S, McCluskey P. HLA-B27 anterior uveitis: immunology and immunopathology. *Ocul Immunol Inflamm* 2016; 24: 450-459.
3. Chan SM, Gan KD, Weis E. Characteristics and predictors of recurrence of anterior and intermediate uveitis in a Canadian referral centre. *Can J Ophthalmol* 2010; 45: 144-148.
4. Seymour R, Ramsey MS. Unusually severe traumatic uveitis associated with occult ankylosing spondylitis. *Can J Ophthalmol* 1991; 26: 156-158.
5. Rosenbaum JT, Tammaro J, Robertson Jr JE. Uveitis precipitated by nonpenetrating ocular trauma. *Am J Ophthalmol* 1991; 112: 392-395.
6. Babu K, Murthy KR. Hypopyon Uveitis Following Band Keratopathy Removal in Ankylosing Spondylitis – A Case Report. *Ocul Immunol Inflamm* 2006; 14: 57-58.
7. Biggioggero M, Crotti C, Becciolini A, et al. The management of acute anterior uveitis complicating spondyloarthritis: present and future. *Biomed Res Int* 2018; 2018: 9460187.
8. Sepah YJ, Akhtar A, Shulman M, Nguyen QD. Traumatic Uveitis. In: Foster CS, Vitale AT. *Diagnosis & Treatment of Uveitis*. Second Edition. JP Medical Ltd. 2013; 1266-1276.
9. Llop SM, Papaliodis GN. Cataract surgery complications in uveitis patients: a review article. *Semin Ophthalmol* 2018; 33: 64-69.
10. Accorinti M, Iannetti L, Liverani M, et al. Clinical features and prognosis of HLA B27-associated acute anterior uveitis in an Italian patient population. *Ocul Immunol Inflamm* 2010; 18: 91-96.
11. Neti N, Pimsri A, Boonsopon S, et al. Triggering factors associated with a new episode of recurrent acute anterior uveitis. *Sci Rep* 2021; 11: 1-6.

