



# Upper eyelid swelling as the first symptom of frontal sinus mucocele in a 9-year-old girl – case report

**Klaudia Rakusiewicz, Agnieszka Czeszyk, Krystyna Kanigowska, Wojciech Hautz**

Department of Pediatric Ophthalmology, Children's Memorial Health Institute, Warsaw, Poland

## ABSTRACT

The aim of the study is to present a case of a 9-year-old girl with mucocele of the frontal sinus penetrating into the anterior fossa of the skull and infiltrating the upper wall of the orbit and manifesting with upper eyelid swelling. On the basis of the clinical

findings and additional imaging tests, the girl was diagnosed with mucocele of the frontal sinus.

**KEY WORDS:** frontal sinus mucocele, eyelid swelling, exophthalmos.

## INTRODUCTION

Edema of the upper eyelid can manifest as varied, frequent ophthalmic diseases, and can also be one of the symptoms of a systemic disease. Mucocele is one of the forms of chronic sinusitis defined as a closed, cystic lesion filled with thick mucus and masses of exfoliated epithelium. It most often occurs in the course of a chronic inflammatory process, allergies, cystic fibrosis, neoplastic and traumatic lesions, congenital stenosis of the natural sinus opening or after laryngological and neurosurgical procedures. Mucocele is usually asymptomatic at first, grows slowly, and over time it can become oppressive and destroy the surrounding tissues. Mucocele can lead to bone osteolysis and thus penetrate into the anterior fossa of the skull and the eye orbit. In the case of infection of the mucus in the sinus, a pyocele is formed, which poses a risk of inflammation of the orbital tissues, meningitis or bone marrow inflammation [1-3].

The disease usually appears in adulthood and affects both sexes with equal frequency. Most often, mucocele develops in the frontal sinus (65-90%), less often in the sphenoid sinus, ethmoid sinus and maxillary sinus [1, 2]. Clinical symptoms of mucocele vary considerably depending on the location. The most common symptoms include headache, nasal obstruction, and changes in facial features. The frontal sinuses are located close to the orbit and brain; therefore, frontal sinus mucocele can spread both intraorbitally and intracranially. When it spreads towards the eye orbit, it can cause dislocation of the eyeball, disturbance in mobility, diplopia, decreased visual acuity and excessive tearing [1, 2]. The proximity

of the frontal sinus mucocele to the brain may pose a risk of mortality if the lesion is left untreated. The most useful tests in the diagnosis of mucocele are computed tomography and magnetic resonance imaging, which enable visualization of the mucocele and the assessment of disease progression and bone destruction. The only treatment method of mucocele is the surgical removal of the cyst with the restoration of proper sinus drainage and simultaneous obliteration of the sinus cavity [2-5].

## CASE REPORT

A 9-year-old girl presented to the Department of Pediatric Ophthalmology of the Children's Memorial Health Institute in Warsaw due to four-week swelling of the upper eyelid of the left eye. Apart from the swelling of the upper eyelid, the girl reported periodic diplopia. Due to an acute allergic eyelid edema diagnosed in another clinic, the child was treated with general antihistamines and topical antibiotic combined with steroid therapy. The expected improvement was not achieved; therefore the patient was referred to the hospital in order to extend the diagnosis and treatment. The history of ophthalmic and systemic diseases was negative. The girl was not taking any general medications or dietary supplements. The history of allergy and trauma was negative. In the performed ophthalmological examination, the best corrected visual acuity (BCVA) in Snellen charts was 1.0 in the right eye and 0.5 in the left eye. The intraocular pressure was 14 millimeters of mercury (mmHg) in the right eye and 23 mmHg in the left eye. Eyeball mobility remained normal,

## CORRESPONDING AUTHOR

Klaudia Rakusiewicz, MD, PhD, Department of Pediatric Ophthalmology, Children's Memorial Health Institute, al. Dzieci Polskich 20, 04-730 Warsaw, Poland

and no diplopia was noted during the examination. The direct and indirect pupil's light reflex was normal. Examination with the exophthalmometer showed a slight asymmetry of the position of the eyeballs: right eye – 13 mm, left eye – 15 mm. The clinical examination revealed a slight, soft swelling of the upper eyelid of the left eye, with a palpable solid mass shifting against the surface, without excessive heat, redness or other symptoms suggesting inflammation. The examination in the slit lamp showed no changes in the anterior segment of both eyeballs. No abnormalities were found on fundus examination of the right eye. In contrast, slightly spiral arterial and venous vessels were noted on the fundus of the left eye (Figure 1). In a test using Ishihara tables, the girl read the colors correctly. Autorefractometry after accommodative paralysis with 1% tropicamide was +0.5 diopters (D) in the right eye, +0.5 –1.25 cylindrical diopters in the left eye. Biometry was 21.26 mm of right eye, 21.62 mm of left eye. No abnormalities were found in the ocular ultrasound examination. On retinal optical coherence tomography (OCT) imaging, macular tomograms were normal, retinal ganglion cell complex thickness and nerve fiber layer thickness were normal in both eyes (Figure 2). In the basic laboratory examination of morphology with smear, neutrophilia (62.1%) was noted. Other tests such as ionogram, glycemia, arginine aminotransferase, asparagine aminotransferase, and creatinine showed no abnormalities. The inflammatory indices passive antibody reaction and C-reactive protein (CRP) remained normal. The patient did not have an elevated body temperature. Magnetic resonance imaging of the head and orbits revealed a multilobulated lesion measuring 23 mm × 27 mm × 10 mm with signal intensity typical of fluid. The lesion protruded into the upper eyelid. After administration of contrast medium, weak enhancement of the cyst walls was seen. The lesion displaced the lacrimal gland downward. The superior and lateral rectus muscles were unchanged, with normal signal intensity, slightly modeled by the lesion (Figure 3). Because the left orbital wall could not be visualized anteriorly, the diagnosis was supplemented with computed tomography (CT) of the head and orbits. Computed tomography imaging showed complete shadowing of the frontal sinuses with bone destruction in the left orbital ceiling and in the posterior wall of the left frontal sinus. There was complete

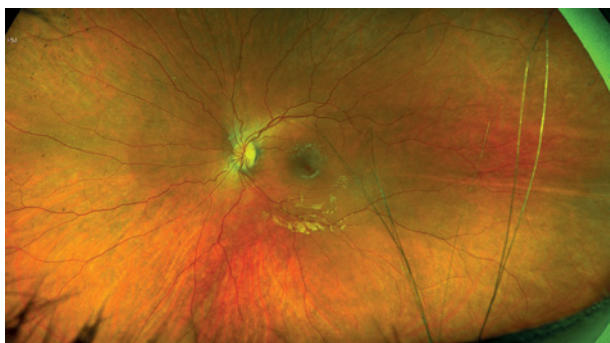


Figure 1. Fundus of the left eye

shadowing of the ethmoid sinuses with thinning of the left cuneiform sinus wall and almost complete maxillary sinuses. On laryngological examination features of chronic sinusitis were found. Based on the whole clinical picture and additional imaging examinations the girl was diagnosed with mucocele of the frontal sinus infiltrating the orbital wall and penetrating to the upper eyelid. After laryngological and neurosurgical consultation it was decided to perform urgent surgical treatment of the lesion.

## DISCUSSION

Unilateral swelling of the upper eyelid occurring in a child is a common reason to consult an ophthalmologist. It is a very uncharacteristic and non-specific symptom that may indicate a variety of ophthalmic as well as systemic diseases. Evaluation of features such as color, hardness, tissue warmth, coexisting eyelid skin lesions, and symmetry of the eyelid crevices along with a carefully taken medical history seems to be essential to diagnose and differentiate the causes of eyelid edema. The differential diagnosis should take into account various inflammatory conditions of the orbit and eyelids as well as neoplastic lesions. Acute allergic eyelid edema has an important place in the differential diagnosis. It is characterized by the sudden appearance of symptoms in response to contact with an allergenic agent, most often pollen or as a result of an insect bite. It is characterized by a non-painful doughy swelling, often of great severity, abutting the palpebral fissure. There is no intense redness or inflammatory changes on the skin. Often the condition is accompanied by conjunctival swelling, tearing, and itching. Allergic eye disease can coexist with asthma, allergic rhinitis and atopic dermatitis [6].

On ophthalmic examination, the patient had no anterior segment changes such as swelling or redness of the conjunctiva, and the patient did not report pruritus. In addition, the girl was previously treated with antihistamines and topical steroid therapy without improvement, so we excluded an allergic cause of the eyelid swelling.

A particularly common infection in children is preseptal cellulitis, where the inflammatory process involves tissues in front of the orbital septum. Causes of this condition include trauma to surrounding tissues predisposing to bacterial infections, severe conjunctivitis, and upper respiratory tract infections. Based on the study of Cürebal *et al.* [7] the most common cause of preseptal cellulitis in children is sinusitis (52.9%). Typically, there is swelling of the eyelids, the skin is tense, with inflammatory reaction, but there is no exophthalmos, mobility disorder or features of conjunctivitis [7, 8].

Much less common in the pediatric population is orbital cellulitis, which is an infection of infectious etiology involving the orbital tissues behind the orbital septum. Aerobic and anaerobic bacteria can be the causative agent. As in preseptal cellulitis, the sources of infection are inflammatory lesions located in the skin of adjacent tissues, inflammatory lesions of the sinuses, subperiosteal abscess, or trauma to the orbital region. The symptoms of the disease include swollen eyelids, erythema, pain, purulent discharge in the conjunctival sac,

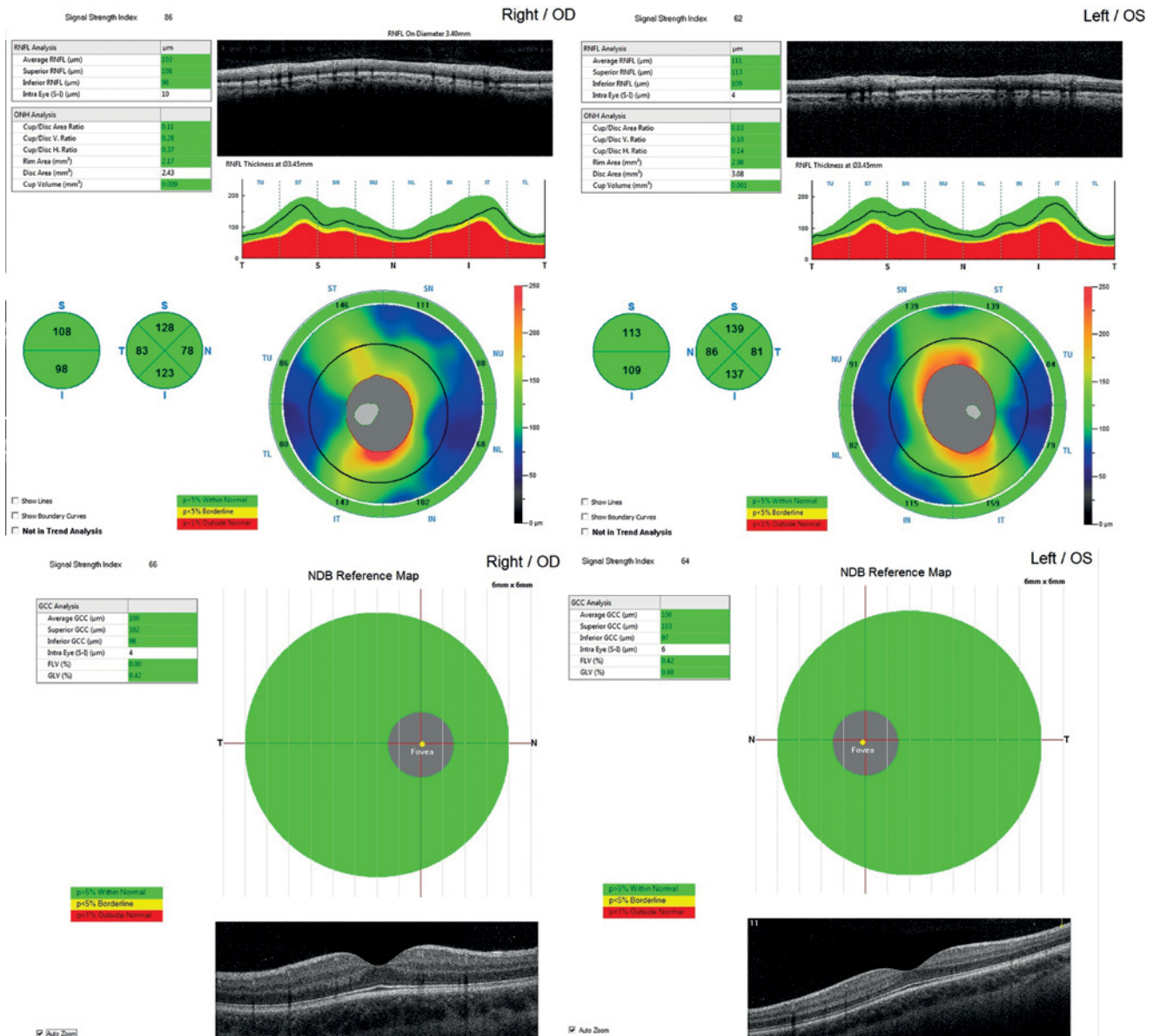


Figure 2. Examination of the retinal ganglion cell complex (GCC) and the retinal nerve fiber layer (RNFL) of both eyes

which is usually accompanied by fever and elevated levels of the inflammatory markers CRP and erythrocyte sedimentation rate (ESR) [9, 10]. In the presented girl, on physical examination we excluded excessive redness and warmth within the affected eyelid, and no purulent secretion was found. In laboratory tests ESR and CRP were normal, and body temperature was not elevated. Because the clinical picture was not consistent with inflammatory lesions of the skin tissue, these diseases were excluded in the differential diagnosis.

Another disease entity that can lead to unilateral swelling of the eyelids is idiopathic orbital inflammatory disease (IOID), formerly referred to as pseudotumor of the orbit. This is a non-infectious, non-neoplastic inflammation involving the orbital tissues [11]. It manifests as swelling of the eyelids, pain on eye movements, and diplopia [12]. Women have

higher incidence of this disease [13]. C-reactive protein and ESR may be elevated in response to inflammation, but are not specific markers for this disease entity [11-13]. The inflammatory process may also involve the extraocular muscles in an isolated manner, in which case the imaging studies show their thickening [12, 13]. Idiopathic orbital inflammatory disease responds very well to treatment with systemic steroid therapy. The imaging examinations performed on the girl did not show any image that could indicate idiopathic orbital inflammatory disease. In laboratory tests, ESR and CRP were normal.

In the pediatric population, the orbit is a very common location for primary and metastatic tumors that manifest as eyelid lesions. The most common benign tumor located in the orbit is capillary hemangioma, which shows proliferation



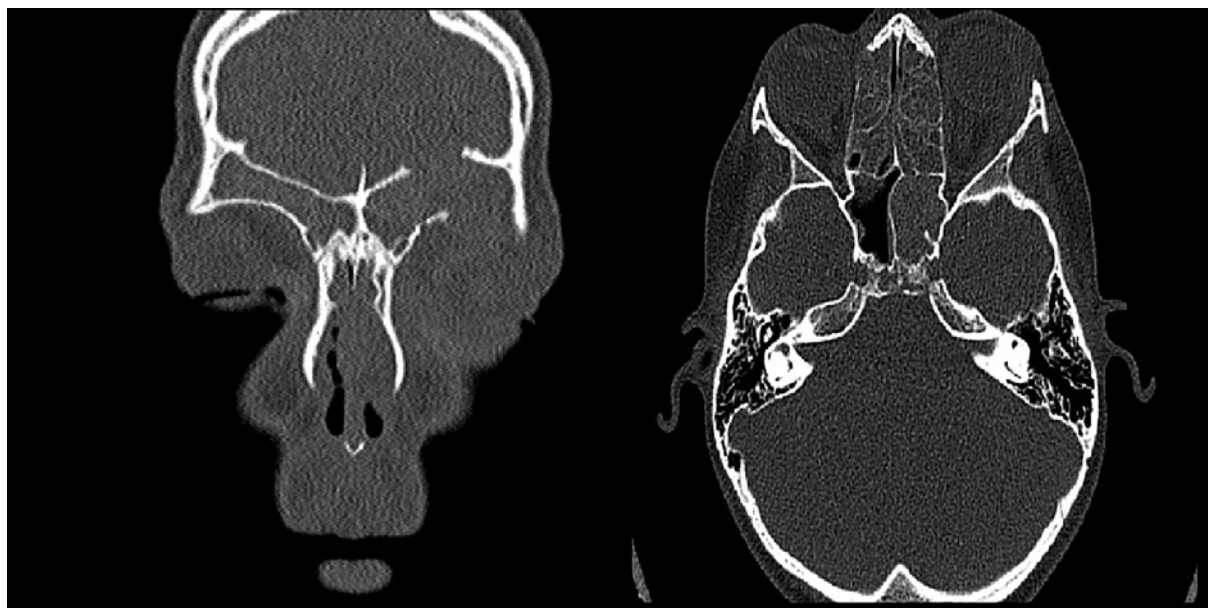


Figure 3. Computed tomography image of the head and orbit

of endothelial cells with narrow vascular channels [14, 15]. In most cases, the capillary hemangioma involves the upper eyelid, making the eyelid skin tight, raised and red. In fewer cases, hemangiomas are located deep in the orbit, in which case the skin is unchanged [16]. It characteristically appears a few weeks after birth and is initially small in size, then grows rapidly over several months. The capillary hemangioma may enlarge when the baby cries due to blood stasis and increased blood pressure [14-16]. However, the most common malignant tumor in children in this location is rhabdomyosarcoma (RMS). In 70% of cases, RMS occurs in the first decade of life, with a higher frequency in boys. Rhabdomyosarcoma manifests with swelling and redness of the skin in the upper nasal orbital region, but the characteristic symptom occurring in 80 to 100% of children is rapidly developing exophthalmos [17, 18]. At diagnosis, imaging studies of the head and orbit are indicated when RMS is suspected. After obtaining a characteristic radiological picture for RMS, further management is to perform a surgical biopsy to confirm the diagnosis on histopathological material [17, 18]. The clinical picture

of the presented disease could indicate a neoplastic process; however, imaging studies excluded the presence of a lesion indicating a proliferative process.

A 9-year-old female patient was diagnosed with frontal sinus mucocele based on physical examination, laboratory tests, and imaging studies. After consultation with the laryngologist and neurosurgical teams, the patient was transferred for treatment of the diagnosed lesion.

## CONCLUSIONS

Frontal sinus mucocele is a rare entity found in children. However, it should be considered in the differential diagnosis of eyelid edema in the pediatric population. Ocular symptoms usually appear late and result from infiltration and destruction of orbital structures. Chronic recurrent swelling of the upper eyelid is an uncommon first sign of frontal sinus mucocele in children.

## DISCLOSURE

The authors declare no conflict of interest.

## References

1. Babiński D, Skorek A, Stankiewicz C, et al. Śluzowiak zatoki czołowej penetrujący do jamy czaszki. *Otolaryngol Pol* 2011; 65: 62-65.
2. Paradowska-Opalka B, Kawczyński M, Jaworowska E, et al. Przewlekłe zmiany zapalne zatok przynosowych penetrujące do oczodołu i przedniego dołu czaszki w materiale Kliniki Otolaryngologii PUM w latach 2010–2012. *Pol Prz Otolarygol* 2013; 2: 21-25.
3. Aggarwal SK, Bhavana K, Keshri A, et al. Frontal sinus mucocele with orbital complications: Management by varied surgical approaches. *Asian J Neurosurg* 2012; 7: 135-140.
4. Mourouzis C, Evans BT, Shenouda E. Late Presentation of a Mucocele of the Frontal Sinus: 50 Years Postinjury. *J Oral Maxillofac Surg* 2008; 66: 1510-1513.
5. Shahi S, Devkota A, Bhandari R, Panth T. Rare giant maxillary mucocele: A rare case report and literature review. *Ann Med Surg* 2019; 43: 68-71.
6. Ono SJ, Abelson MB. Allergic conjunctivitis: update on pathophysiology and prospects for future treatment. *J Allergy Clin Immunol* 2005; 115: 118-122.
7. Cürebal B, Şahin A, Dalgıç N. Preseptal Cellulitis in Children: A Single-Center Experience. *Sisli Etfal Hastan Tip Bul* 2019; 53: 409-412.

8. Santos JC, Pinto S, Ferreira S, et al. Pediatric preseptal and orbital cellulitis: A 10-year experience. *Int J Pediatr Otorhinolaryngol* 2019; 120: 82-88.
9. Daoudi A, Ajdakar S, Rada N et al. [Orbital and periorbital cellulitis in children. Epidemiological, clinical, therapeutic aspects and course]. *J Fr Ophtalmol* 2016; 39: 609-614 [Article in French].
10. Saadouli D, Yahyaoui S, Ben Mansour K, et al. [Orbital cellulitis in children: Report of 60 cases]. *J Fr Ophtalmol* 2019; 42: 1056-1061 [Article in French].
11. Schoser BG. Ocular myositis: diagnostic assessment, differential diagnoses, and therapy of a rare muscle disease – five new cases and review. *Clin Ophthalmol* 2007; 1: 37-42.
12. Yeşiltaş YS, Gündüz AK. Idiopathic Orbital Inflammation: Review of Literature and New Advances. *Middle East Afr J Ophthalmol* 2018; 25: 71-80.
13. Yuen SJ, Rubin PA. Idiopathic orbital inflammation: distribution, clinical features, and treatment outcome. *Arch Ophthalmol* 2003; 121: 491-499.
14. Bang GM, Setabutr P. Periocular capillary hemangiomas: indications and options for treatment. *Middle East Afr J Ophthalmol* 2010; 17: 121-128.
15. Haggstrom AN, Drolet BA, Baselga E, et al. Prospective study of infantile hemangiomas: clinical characteristics predicting complications and treatment. *Pediatrics* 2006; 118: 882-887.
16. Kushner BJ. Hemangiomas. *Arch Ophthalmol* 2000; 118: 835-836.
17. Rao AA, Naheedy JH, Chen JY, et al. A clinical update and radiologic review of pediatric orbital and ocular tumors. *J Oncol* 2013; 2013: 975908.
18. Jurdy L, Merks JH, Pieters BR, et al. Orbital rhabdomyosarcomas: A review. *Saudi J Ophthalmol* 2013; 27: 167-175.