



Surgery for refractory glaucoma using the Ahmed valve, mainly in the author's modification of the implantation technique. Six years' own clinical experience with selected case reports

Adam Cywiński

Silesian Eye Treatment Center, Żory, Poland

ABSTRACT

Aim of study: Retrospective analysis of patient outcomes during six years' own clinical experience with Ahmed valve implants, including the benefits, and the author's original modification of the implantation technique.

Results: Normalization of intraocular pressure (IOP) was achieved in the majority of patients undergoing the procedure, though some of them required additional topical hypotensive medications or IOP-lowering procedures. In two patients (three eyes), innovative combination procedures were performed to preserve and improve vision.

Conclusions: IOP reduction surgery using the Ahmed valve is a safe procedure with long-lasting outcomes in terms of low-

ring and normalizing intraocular pressure. A prerequisite for employing the author's modification of valve tube implantation in the vitreous chamber is posterior vitrectomy. The modification helps prevent the most common postoperative complications associated with tube implantation in the anterior chamber and vitreous body. It needs to be highlighted that this treatment modality is one of only a few reversible methods used in the therapy of glaucoma, but it should be performed without delay to avoid irreversible loss of optic nerve function.

KEY WORDS: Ahmed valve, refractory glaucoma, transscleral fixation, posterior vitrectomy, diabetes mellitus.

INTRODUCTION

Refractory glaucoma is a common type of persistent increase in the intraocular pressure, which cannot be adequately controlled with standard conservative and surgical methods, mostly because of complete and permanent obstruction of the outflow of aqueous humor through the drainage angle of the eye.

The expression "complete obstruction of aqueous humor outflow" carries a clear message and has specific implications. The causes of refractory glaucoma are manifold, ranging from congenital lesions caused, among other factors, by dysgenesis of the drainage angle, to the most commonly occurring acquired pathologies.

Among the latter, ocular complications of diabetes mellitus are the most widespread cause of permanent "blockage" of the angle of drainage due to abnormal growth of fibrovascular tissue associated with significant hypoxia of ocular structures.

Other underlying causes of this form of glaucoma include post-traumatic ocular conditions and retinal

venous thrombosis. It needs to be stressed that secondary glaucoma, resulting from post-thrombotic abnormalities, can be prevented by timely initiation of anti-VEGF therapy (immediately after the occurrence of thrombotic changes) [1]. Yet other conditions potentially leading to complete and permanent obstruction of the drainage angle include post-inflammatory changes and complications of vitreous surgery (silicone oil emulsification).

When discussing complete blockage of the drainage angle, consideration should also be given to malignant glaucoma. In this type of glaucoma, both the pathogenesis leading to angle closure and the treatment are quite different. Consequently, certain therapeutic modalities – such as standard trabeculectomy or cyclodestructive procedures – are not only unacceptable but should be excluded altogether. Where no therapeutically beneficial effects are achieved with non-surgical methods, the only effective type of treatment is posterior vitrectomy, which the author sought to demonstrate in the paper *Causes of failures in the treatment of malignant glaucoma after cataract removal based on an analysis of several*

CORRESPONDING AUTHOR

Adam Cywiński, MD, PhD, Śląskie Centrum Leczenia Oczu, ul. Okrężna 11, 44-240 Żory, e-mail: adamcyw@gmail.com




Figure 1. OCT of the anterior segment of the eye in a patient with malignant glaucoma. Visible contact between the iris and the cornea (extending over 360°), causing complete closure of the drainage angle. Source: Silesian Eye Treatment Center

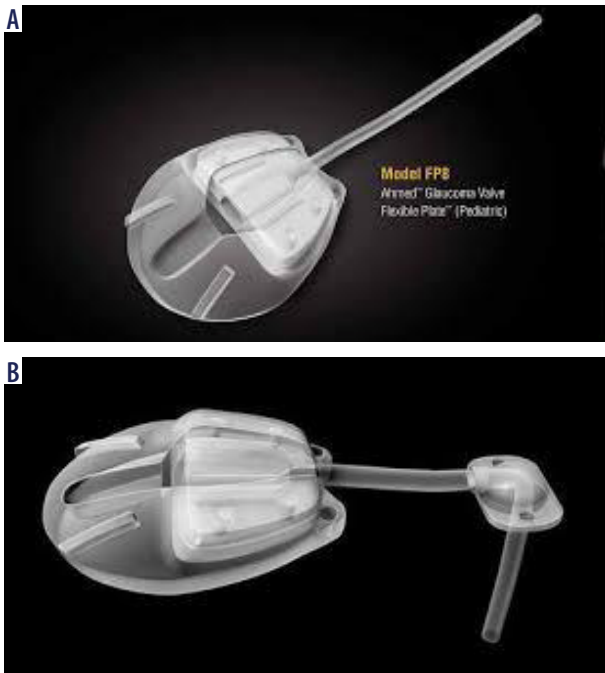


Figure 2. Ahmed valve. A) Model with tube draining fluid from the anterior chamber. B) Model with tube draining fluid from the vitreous chamber. A fixed element of valve design is the adapter redirecting the tube, usually covered with freeze-dried cornea or sclera

case studies, describing cases of unsuccessful treatment of malignant glaucoma [2]. In patients with this type of glaucoma, the closure of the drainage angle is reversible if appropriate therapy is initiated in a reasonably short time, typically within a few days of the uncontrolled IOP increase being detected (Fig. 1).

One of the primary symptoms of refractory glaucoma is very high IOP, reaching values of 40 to 60 mmHg, which does not decrease after conservative topical and systemic treatment [3, 4]. As mentioned above, the underlying condition is complete and irreversible blockage of the outflow of the aqueous humor through the drainage angle. In such situations, performing a cyclodestructive procedure as the treatment of choice has no justification. Achieving a balance between the inflow – or production – of the aqueous humor, and its outflow, would require complete destruction of the ciliary body. This unfavorable treatment modality should not be employed, especially in patients with preserved visual function. Cyclodestructive procedures should be performed in eyes with moderately elevated intraocular pressure, in which

the outflow through the drainage angle is still maintained, or in totally blind eyes [5].

The presence of pathological vascularity in the drainage angle is also a contraindication to standard trabeculectomy because of its known lack of efficacy. Trabeculectomy with mitomycin is associated with better – though still not very favorable – control of postoperative intraocular pressure (IOP) [6–8]. Despite this knowledge, the surgical procedures listed above continue to be performed, exposing the patient to unnecessary pain and the healthcare system to the burden of avoidable financial expenditures.

What is the recommended treatment then? The method of choice should aim at creating an alternate pathway for the outflow of aqueous fluid from the eye. One of such methods, which has been widely used worldwide for almost 30 years, is the implantation of the Ahmed valve, one of the available anti-glaucoma drainage systems [3]. There are two main ways of placing the Ahmed valve tube in the eye: in the anterior chamber and in the vitreous chamber. Accordingly, different valve models have been developed (Figures 2A and B).

Like any other form of therapy, the implantation of a drainage system, such as the Ahmed valve, has its limitations and potential adverse sequelae. The main contraindications and disadvantages associated with the use of anterior-chamber valve models include the inability to insert the valve tube if the anterior chamber is too shallow, or decompensation of the cornea if it comes into contact with the valve tube. Conjunctival puncture due to contact with the so-called adapter (an element of the valve placed in the vitreous chamber, designed for redirecting the tube) or conjunctival erosion caused by the tissues covering this element (freeze-dried cornea, sclera), are among other reported causes of complications and treatment failures [9]. Based on negative own experiences, the author of this article developed an original modification of the technique with the aim of avoiding most of the reported complications. The technique of the procedure is described in the 2019 paper *A Treatment of Refractory Glaucoma in Pseudophakic Patients after Posterior Vitrectomy using the Ahmed Valve in an Own Modification* [10]. The modification involves implantation of the cheaper, anterior-chamber type of the Ahmed valve which drainage tube is placed directly in the vitreous chamber instead of the anterior chamber. The method eliminates the use of the more expensive valve model which carries the fluid out of the eye from the vitreous chamber.

Rationale behind the modification

The author's first own experiences, dating back 17 years, involved a valve model with a tube inserted into the vitreous chamber (Figure 2B). In cases of refractory glaucoma developing after posterior vitrectomy, the author primarily used the model with an adapter. Unfortunately, covering the valve adapter (i.e. part of the valve that changes the direction of the tube) only by the conjunctiva resulted in conjunctival puncture within 7 to 14 days of insertion

in eight out of eight patients undergoing the procedure, with all the ensuing adverse reactions: eye pain, recurrent inflammation, and ocular irritation. The valve was removed, causing an uncontrolled increase in the IOP again. In subsequent four cases, covering the adapter with tissue (freeze-dried cornea in two cases and freeze-dried sclera in another two eyes), failed to provide a lasting effect, either. In three cases, the conjunctiva was punctured by the freeze-dried element covering the valve adapter. In the fourth case, chronic inflammation of the ocular surface at the site of contact with the freeze-dried tissue prompted its removal. Consequently, in two of the cases mentioned above the author decided to remove the freeze-dried tissue along with the adapter, without removing the entire valve. Following the removal of these elements and formation of an intrascleral tunnel, at the end of which an entry into the eye was established at a distance of 3.5 to 4 mm from the corneal limbus. Subsequently, the tube was reinserted into the vitreous chamber. Since the IOP-lowering effect was long-lasting, and no postoperative complications were noted, the author proposed his own modification of the valve implantation technique. This simple modification practically did not change the way the valve tube was inserted into the eye and did not necessitate the introduction of a completely new, previously unknown, valve model. Nonetheless, it helped to improve the therapeutic efficacy of the procedure by reducing the risk of the above-described adverse effects associated with valve implantation. Since the only difference between the two valve models (Figures 2A and B) is the presence of the adapter, in view of the benefits obtained in the two cases presented above, the author decided to use exclusively the anterior-chamber model, with the tube inserted into the vitreous chamber instead of the anterior chamber. The prerequisite for performing the modified procedure is an eye that is partially or completely devoid of the vitreous body.

In addition to the standard steps of the procedure, such as fixation of the valve in the subconjunctival space, the author's modification includes:

- formation of a 3–4 mm long intrascleral tunnel, at the end of which, 3.5–4.0 mm from the limbus, an entry into the eye is established using a 20G vitrectomy knife (MVR),
- fixation of the tube in the vitreous chamber behind the lens. The tube must be visible in the pupillary area immediately upon insertion into the eye [10].

AIM OF STUDY

Retrospective review to evaluate the outcomes of patients after implantation of the Ahmed valve drainage system in the author's modification in the treatment of refractory glaucoma.

MATERIAL AND METHODS

Valve implantation procedures were performed in two main variants, with five exceptions. One variant involved standard insertion of the valve tube into the anterior chamber of the eye. In the other variant, the valve tube was inserted



Figure 3. Ahmed valve model FP7, a standard device used in the presented patient group. Source: own photo of the packaging of the purchased valve

into the vitreous chamber using the author's modified technique. The exceptions mentioned above involved removing the adapter from the tube of the model designed for placement in the vitreous chamber and reinserting it in the same location (two eyes). The reason was conjunctival puncture caused by the material used to cover the valve adapter. Two further exceptions consisted in tube removal from the anterior chamber and its insertion into the vitreous chamber. In the fifth exception, the Ahmed valve was replaced with another model after spontaneous eversion of the tube from the anterior chamber. The tube was subsequently placed in the anterior chamber.

In all cases except those described above, the anterior-chamber valve model FP7 was used (Figure 3). All the procedures were performed in a private medical center (Silesian Eye Treatment Center in Żory) as part of the center's same-day surgery scheme. Some of the procedures were combined with another ocular procedure. The primary purpose of the surgery was to normalize the intraocular pressure of the eye. Unfortunately, in some cases this was the only beneficial postoperative effect. Some of these patients had irreversibly lost vision due to glaucomatous damage to the optic nerve in the process of often lengthy and ineffective treatment.

Standard preoperative and postoperative examinations included assessment of distance and near visual acuity (where it was possible), anterior and posterior segments of the eye, corneal pachymetry, and endothelial cell count. In each case, the drainage angle was evaluated by gonioscopy.

RESULTS

Valve implantation was performed in a total of 38 patients, including three patients with bilateral implantation. Twenty four patients (over 63% of the whole group) were virtually monocular. Eleven (28.9%) patients were found to have total blindness (loss of light perception) in the other eye.

In the majority of patients (over 56%) in this group, refractory glaucoma developed due to ocular complications of diabetes mellitus.

The mean follow-up period was 21 months (range: 2 to 66 months).

The patients were divided into two groups, based on the evaluated chance of vision preservation and improvement.

One group consisted of 10 patients with advanced glaucomatous neuropathy and thus irreversible vision loss. Eight patients in the group were monocular. The aim of the procedure was to preserve residual vision by normalizing intraocular pressure and preventing the onset of late complications associated with very high IOP, including continuous pain and bullous keratopathy, but primarily complete loss of vision. The valve implantation procedure was carried out in 10 patients, aged 8 to 82 years (total of 11 eyes). In five patients, the procedure was performed in combination with one to three other procedures. The mean number of prior

anti-glaucoma procedures was three, and they were primarily cyclodestructive procedures performed with a diode laser (TSCPC) and trabeculectomy (TB). Pre- and postoperative distance visual acuity did not exceed 2.3 logMAR. Preoperatively, the IOP reached values in the range of 38 to 57 mmHg. Postoperatively, it varied from 9 to 25 mmHg. The mean follow-up period was 23 months.

For three cases in this group, a more in-depth discussion is warranted.

Case report 1

Female patient with Down's syndrome, aged 18. Diagnosis: status post congenital cataract removal, pseudophakia in both eyes. Marked shallowing of the anterior chamber; peripheral, circular iridocorneal adhesion completely blocking the drainage angle, almost absolute glaucoma, practical blindness in the left eye.

On the day of the first appointment: left eye – distance visual acuity = 3.0 logMAR, IOP = 36 mmHg (with topical anti-glaucoma medications (TAGM) and systemic acetazolamide). The patient had several prior anti-glaucoma procedures in her left eye, including TB (twice) and TSCPC (twice). Since the treatment was unsuccessful, no further surgical therapies were attempted. Right eye – glaucoma controlled with topical medications.

It was decided to opt for an innovative combined procedure, not previously performed in Poland. The first step in the surgical procedure was posterior vitrectomy in preparation for the implantation of the Ahmed valve tube, using the author's modified technique, into the vitreous chamber. Postoperative follow-up period: 26 months.

At the final follow-up appointment, the IOP was 21 mmHg, and visual acuity was maintained at the same level.

Case report 2

Female patient, aged 8. Diagnosis: glaucoma, congenital aniridia, drainage angle dysgenesis, cataract in both eyes. Refractory glaucoma (almost absolute), practical blindness in the left eye. Right eye – chronic glaucoma controlled with topical medications.

Prior anti-glaucoma procedures performed in the left eye during hospitalizations in two treatment centers spanning several weeks: TB (three times), TSCPC (twice). Since the IOP could not be controlled, no further surgical therapies were attempted.

On the day of the first appointment: left eye – distance visual acuity = 3.0 logMAR, IOP = 40 mmHg (with TAGM and systemic acetazolamide).

In the left eye, the tube of the Ahmed valve was placed in the anterior chamber, in an unusual location, i.e. in the inferior temporal quadrant, as the conjunctiva in the superior quadrants could not be separated mainly due to scleroconjunctival adhesions after previous procedures. The IOP in the left eye normalized at 20 mmHg. Cataract removal surgery was performed in both eyes due to cataract progression.

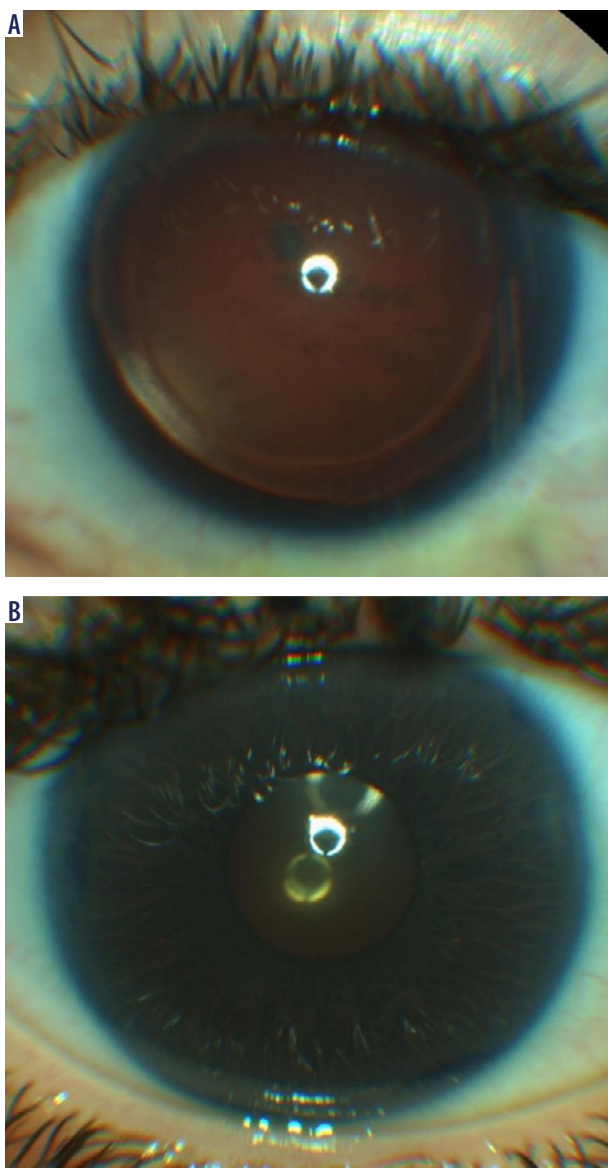


Figure 4. Female patient, aged 8. A) Status post Ahmed valve implantation, pseudophakia, almost absolute glaucoma in the left eye. Valve tube visible in the anterior chamber in the inferotemporal quadrant. Source: Silesian Eye Treatment Center. B) Status post Ahmed valve placement in the anterior chamber and artificial iris implantation, pseudophakia of the right eye. Source: Silesian Eye Treatment Center

In the right eye, cataract removal was combined with the implantation of an artificial iris. Visual acuity in this eye improved from 2.0 to 0.9 logMAR. After two months, the IOP in the right eye increased to more than 35 mmHg despite treatment with topical anti-glaucoma medications and systemic acetazolamide. Ahmed valve implantation in the anterior chamber was performed. The IOP reached values of 18 to 21 mmHg and has remained at this level for eight months. In the other eye, the IOP rose to more than 30 mmHg after cataract removal – despite treatment with anti-glaucoma medications – and corneal edema appeared again. In this eye, 180-degree ECP was additionally performed. The IOP normalized (15–20 mmHg) and corneal edema resolved (Figures 4A and B).

Postoperative follow-up period: 26 months.

At the final follow-up appointment, the IOP was 18 mmHg. Visual acuity deteriorated from 3.0 logMAR to counting fingers in front of the eye.

Case report 3

Male patient, aged 82. Diagnosis: glaucoma (absolute in the left eye, almost absolute in the right eye). Right eye: visual acuity 3.0 logMAR, significant narrowing of the visual field, IOP = 31 mmHg despite treatment with TAGM and acetazolamide. Two prior TB and two TSCPC procedures done in the eye.

Since the IOP failed to normalize, Ahmed valve implantation was performed at another center in the standard location, i.e. in the anterior chamber. Immediately after valve insertion, total choroidal detachment occurred, followed by abolition of the anterior chamber of the eye. With time, the choroidal detachment resolved and the anterior chamber only slightly deepened. However, the peripheral iridocorneal adhesion persisted along with progressive corneal edema and haze caused by contact between the cornea and the valve tube. In one of the clinical centers, the patient was scheduled for Ahmed valve removal. However, the author of this paper chose a different option. Following partial removal of the vitreous from the space behind the lens (partial posterior vitrectomy was possible because of the features of vitreous detachment and low risk of retinal detachment), the valve tube was transferred to the vitreous chamber by applying the author's modified technique. Corneal edema and haze resolved approximately five weeks after the procedure. The IOP reached 8–10 mmHg, and visual acuity remained at one meter viewing distance. The follow-up period was 18 months.

The Ahmed valve tube was repositioned from the anterior chamber to the vitreous chamber in three eyes. A sample procedure comprising tube repositioning and silicone oil removal is shown in the video at:

<https://medtube.pl/okulistyka/filmy-medyczne/31078-przesuniecie-rurki-zastawki-ahmeda-w-polaczeniu-z-usunieciami-oleju-silikonowego>.

The other group was made up of patients who had retained functional vision or who were identified as having a chance of vision improvement.

The valve implantation procedure was performed in 28 patients (30 eyes) aged 19 to 81 years. In nine patients, the procedure was combined with one to three other procedures. Similarly to the former group, the mean number of prior glaucoma procedures (mainly TSCPC and TB) was three. Distance visual acuity – preoperative: from counting fingers in front of the eye to 0.6 logMAR (mean: 0.8 logMAR); postoperative: from 3.0 to 0.2 logMAR (mean: 0.7 logMAR). Preoperatively, the IOP reached values in the range of 32 to 62 mmHg. Postoperatively, it varied from 9 to 24 mmHg. The mean follow-up period was 23 months. Vision improvement was observed in 10 eyes, and deterioration in three eyes.

In this group, more attention needs to be paid to further two patients.

Case report 4

Male patient, aged 66. Diagnosis: practical blindness in the right eye. Status post PPV due to diabetic ocular complications, pseudophakia, status post Ahmed valve implantation in the anterior chamber in a typical location (performed at another center).

Reason for ophthalmic consultation: sudden increase in the IOP in the seeing eye.

On the day of consultation: distance visual acuity (BVA) = 0.6 logMAR, near visual acuity D-075 (Snellen), IOP = 40 mmHg. The cause of the IOP increase was the eversion of the valve tube beyond the anterior chamber of the eye.

The patient was offered the option of valve tube placement using the author's modified technique, i.e. in the vitreous chamber. During the procedure, it was revealed that the valve tube had become completely obstructed. The valve was removed. A new valve was implanted, also using the author's modified technique. The follow-up period was 66 months. At the final follow-up appointment: distance visual acuity (BVA) = 0.5 logMAR, near visual acuity D-0.75 (Snellen), IOP = 18 mmHg.

Case report 5

Male patient, aged 39. The aim of the consultation was to determine the possibility of reducing the IOP in both eyes. At the appointment, the IOP values were at 45 and 40 mmHg in the right and left eyes, respectively (on TAGM). Distance visual acuity (BVA): corrected +12.0 Dpsh, right eye = 0.7, left eye 1.0 logMAR. Exotropia in the left eye. Features of advanced glaucomatous neuropathy were identified in both eyes. In the left eye, glaucoma was almost absolute.

The patient had a very complex history of ophthalmic treatment. Binocular aphakia due to removal of congenital cataract in childhood. A year before the consultation, the patient had retinal detachment in both eyes. The retina was reattached in both eyes by posterior vitrectomy. Unfortunately, after silicone oil removal, the IOP rose to high levels, above 50 mmHg, and failed to drop despite therapy, including two TB procedures in the better-seeing right eye.

Table I. Summary of conditions followed by the development of refractory glaucoma

Refractory glaucoma secondary to other disorders	Number of eyes
Ocular complications of diabetes mellitus	28
Eye injury	2
Silicone oil emulsification	2
High myopia	2
Recurrent anterior uveitis	2
Congenital aniridia	2
Malignant glaucoma	1
Glaucoma – carotid artery stenosis	1
Glaucoma secondary to congenital cataract removal	1

Table II. Method of Ahmed valve tube implantation

Implantation technique	Number of eyes
Author's modified technique	24
In the anterior chamber	12
Repositioning of the valve tube from the anterior chamber to the vitreous chamber	2
Removal of the adapter followed by reinsertion of the tube into the vitreous chamber	2
Valve replacement due to tube eversion and migration from the anterior chamber of the eye	1

Table III. Ahmed valve implantation combined with other surgical procedures

Type of valve implantation	Number of eyes (patients)
Ahmed valve as a separate procedure	27
PPV with silicone oil endotamponade + valve implanted in the anterior chamber	5
PPV + valve implanted in the vitreous chamber	2
PPV + Z + W + valve implanted in the vitreous chamber	4
Z + W + valve implanted in the vitreous chamber	1
Intrascleral lens fixation + valve implanted in the vitreous chamber	2 (1)

The patient was offered an innovative procedure combining intrascleral fixation with Ahmed valve implantation using the author's modified technique. The procedure was performed concurrently, bilaterally. In addition, residual emulsified oil was removed from the left eye.

The postoperative follow-up period was three months. Without the need for additional correction, BVA remained at the level given above. The IOP in both eyes achieved values of 19 to 23 mmHg, and the retina remained adherent.

Table IV. Postoperative complications

Complication	Number of eyes
Corneal edema (transient)	25
Postoperative hypotony (transient)	15
Progressive corneal edema (valve in the anterior chamber)	5
Postoperative IOP between 23 and 28 mmHg	12
Punctate corneal epithelial defects (transient)	2
Mild IOP reduction	2
Choroidal detachment (another center)	1
No IOP reduction (transient)	2
Complete loss of vision (not directly related to glaucoma)	2

IOP – intraocular pressure

Video showing the procedure:

<https://medtube.pl/okulistyka/filmy-medyczne/32431-jednoczasowe-zalozenie-zastawki-ahmeda-w-polaczeniu-z-fiksacja-srodtwardowkowa-soczewki-soleko-carleval-e-wykonane-obiocznie-u-pacjenta-z-mental-retardation>.

In total, a total of 41 Ahmed valve implantations were performed during the six-year period. Twenty-seven valves were implanted as a single procedure, and a total of 14 procedures were performed in combination with other ophthalmic surgeries. In three patients, the procedure was done in both eyes.

Table I presents a summary of conditions followed by the development of refractory glaucoma.

Valve tube implantation methods are listed in Table II.

The valve was implanted in the eye as a single procedure or in combination with other surgeries.

Table III lists all combinations of valve implantation with other surgical procedures.

Valve implantation due to an unusual cause

Case report 6

The procedure was performed in a 64-year-old monocular patient. Ocular complications of diabetes mellitus led to vision loss in the right eye. In 2016, a PPV procedure was performed in the left (pseudophakic) eye for the above reason. Three months later, a 360-degree ECP procedure was carried out because of features of refractory glaucoma, reducing the IOP to less than 20 mmHg. During a follow-up period of more than five years, recurrent hemorrhages into the vitreous body occurred a total of 11 times, necessitating four interventions (surgical evacuation of blood from the vitreous chamber). Importantly, during each of these interventions, the fluid filling the chamber had a syrup-like consistency. Based on these findings, it was decided to perform the implantation procedure by placing the tube in the vitreous chamber. The procedure was carried out with

the following assumptions: 1) the vitreous chamber would 'clear' faster, assuming repeated hemorrhage, 2) the constant filtration of fluid in the chamber would eliminate the risk of accumulation of vascular endothelial growth factors (VEGFs), thereby reducing the threat of hemorrhage recurrence.

Postoperative complications are listed in Table IV.

Case report 7

Male patient, aged 31. Diagnosis: ocular complications of diabetes mellitus. Blindness in the right eye. Refractory glaucoma, status post TSCPC (twice), status post posterior vitrectomy with silicone oil endotamponade, pseudophakia of the left eye.

On the day of the consultation, visual acuity in the left eye was assessed as the perception of movement, and the IOP was 38 mmHg despite treatment with anti-glaucoma medication. The patient was referred in one of the clinical centers for yet another (third) diode laser therapy despite a reported decline in vision after the previous two procedures. Silicone oil was left in the eye for five years out of concern about possible complications after its removal. The retina was attached, with visible peripheral retinotomy extending over 360 degrees.

The patient was offered and underwent a combined procedure consisting of silicone oil removal and Ahmed valve tube placement in the vitreous chamber, by applying the author's modified technique. Two months after surgery, the patient's visual acuity improved to 10 letters from two meters (logMAR), IOP 17 mmHg, without any additional medications.

Comment: Both hypotony and corneal edema typically resolved by 14 days after the procedure. Hypotony was more commonly observed in eyes undergoing combined procedures, e.g. with posterior vitrectomy or silicone oil removal. Corneal edema occurs primarily in the eyes in which the IOP was elevated for a prolonged period prior to surgery, or in patients with concurrent cataract surgery.

In cases of progressive corneal edema, mainly due to contact between the valve tube and the cornea, the valve was repositioned into the vitreous chamber (two eyes) in a combined procedure comprising silicone oil removal from the vitreous chamber.

In only one case, in an eye with visual acuity at the level of light perception secondary to incorrectly treated CRVO with features of ischemia, corneal edema decreased only slightly.

No reduction in the IOP was noted in two eyes. In one case, the valve tube was inserted into the suprachoroidal space. Following adjustment, the IOP level normalized. Therefore, a very important element of Cywiński's modification of the procedure is checking that the valve tube is placed in the vitreous chamber.

In the other case, the valve tube was inserted into the vitreous chamber of the eye in which the IOP remained normal for three months after a combined PPV/ECP procedure, and

then rose rapidly. During the repeated surgery and inspection of the patency of the valve tube, it was revealed that the tube was blocked by very thick intraocular fluid with a syrup-like consistency.

The increase in intraocular fluid density is the study author's own observation. It is possible that in virtually every eye in which cyclodestructive procedures are performed – and hence intraocular fluid production is reduced – the fluid may become thicker, leading to a number of consequences including an increase in VEGF levels.

In patients with IOP elevation to 23–28 mmHg, the effect was observed approximately one month after treatment. Based on the author's own experience, in all cases where elevated IOP is detected, the recommended option is massaging the eyeball, with attention given to whether the bleb surrounding the Ahmed valve changes in size. The effect of bleb enlargement is a positive sign. In such eyes, daily eyeball massage is recommended to create a permanent space around the bleb. Very deep placement of the valve in the orbit increases the risk of elevated IOP after surgery. In two cases, the IOP reached a value of about 28 to 30 mmHg despite treatment with topical IOP-lowering agents. In one eye, with high preoperative myopia (–25 Dsph), an additional 180-degree ECP procedure was performed. The case shows that in patients with very large eyes it might be advisable to implant valves with a larger drainage area, consisting of two drainage components. In the other case, treatment with IOP-lowering drugs led to the normalization of pressure.

Two patients experienced complete loss of vision. Progression of optic nerve atrophy accompanied by significant retinal ischemia secondary to renal failure and subsequent dialysis therapy led to blindness in one of the patients. In the other patient, loss of vision was due to recurrent hemorrhages secondary to ischemic CRVO, untreated with anti-VEGF therapy. In both cases, IOP normalization was achieved, and even a hypotonic effect ensued with time.

DISCUSSION

Following a review of the outcomes of the procedures reported above and the condition of the eyes in patients referred for this type of surgery, a number of conclusions emerge.

1. Cyclodestructive treatments performed with a diode laser are the most common 'therapy' for very high IOP. They are also used in eyes with preserved (and often even good) visual acuity. Leaving aside the issue of ignoring global indications for this type of surgery, which provide that the procedure can be performed safely in blind eyes, this treatment is 'a cure for virtually all types of glaucoma', from refractory to malignant.
2. The process of IOP-lowering treatment is very protracted in time, which has a range of serious negative consequences including, in some patients, permanent total loss of vision. In the presented study material, more than 10% of patients lost their vision irreversibly. Even though these patients were often treated for many months

and underwent a number of IOP-lowering procedures, the outcome was unsatisfactory, including vision loss due to absolute glaucoma. Such ineffective treatment, particularly in children, condemns them to irreversible blindness during the most important period of their lives. More than 60% of all patients in this group are monocular and lost their vision for two main reasons: ocular complications of diabetes mellitus and inadequately treated secondary glaucoma.

3. Inadequate selection of surgical IOP-lowering interventions. Procedures such as trabeculectomy, often performed repeatedly in eyes with visible vascular pathologies within the drainage angle or in very young people, in post-inflammatory eyes, are doomed to failure from the outset. The same applies to the treatment of malignant glaucoma. In addition to resulting in therapeutic failure with its associated consequences, inappropriate choice of treatment modality also causes significant economic losses [2].
4. A review of the above group of patients shows that the scope of IOP-lowering procedures used in the treatment of refractory glaucoma is essentially restricted to filtration shunt procedures and interventions reducing the production of the aqueous fluid. There were virtually no procedures aimed at creating a new pathway for the outflow of the aqueous fluid from the eye in a safe and effective manner, even though such procedures had been performed worldwide for over 30 years.
5. Another conclusion from the review of treatment outcomes in this group is high efficacy of lowering the IOP and preserving or even improving vision, and high safety of the Ahmed valve implantation procedure, either performed alone or in combination with other – even highly specialized – surgical procedures. The author's modified technique prevents the adverse effects associated with the presence of the tube in the anterior chamber, mainly progressive keratopathy, and conjunctival puncture caused by the element of the valve fitted with a tube inserted into the vitreous chamber. The modification proposed by the author of this paper also allows for the successful management of progressive keratopathy without complete removal of the well-functioning valve.
6. The key element in the management of refractory glaucoma is timely initiation of an effective IOP-lowering treatment and prompt response to high eye pressure in patients who fail to achieve the intended IOP reduction after the selected surgical procedure.
7. Maintaining silicone oil in the eye for an excessively long period of time, mainly out of concern about the effects of its removal and leading to considerable emulsification. In such cases, it would be sufficient to refer patients to a specialist who has no such concerns and who is more experienced in the treatment of retinal conditions.

The author's modification of the technique of Ahmed valve implantation carries a range of benefits, including those listed below.

1. Complete elimination of the risk of complications associated with valve tube placement in the anterior chamber, as none of the valve components come into contact with the structures of the anterior segment of the eye. The most common complication linked to the presence of the valve tube in the anterior chamber is corneal decompensation. Its prevalence, as reported by various authors, ranges from 7 to 27% [11, 12]. According to more optimistic estimates, decompensation occurs in 3.5% of patients over a five-year follow-up period [13]. Another comparative study showed a clear and significant decrease in endothelial cell count in patients with valve tube implanted in the anterior chamber compared to those with the tube implanted in the vitreous chamber, during a follow-up of over two years [14].
In the study group, corneal decompensation occurred only in a proportion of cases, in which the tube was placed in the anterior chamber. For this reason, after a reduced endothelial cell count and increasing edema were found, the valve tube was repositioned into the vitreous chamber.
2. Prevention of complications associated with the implantation of a valve model with an adapter in which the tube is placed in the vitreous chamber. In the study group, there were no cases of conjunctival puncture by any valve component. The presence of foreign tissue covering the adapter is associated not only with the risk of conjunctival erosion (in up to 6% of cases), but also with the development of chronic inflammation, softening of the eye tissues, and even endophthalmitis [15]. Similar statistics regarding the risk of conjunctival puncture by valve components (2–7%) were reported in an earlier paper [16], which also highlighted the need for other ocular repair procedures.
3. Halting of progressive corneal decompensation caused by contact between the valve tube and the cornea by removing it from the anterior chamber and placing it in the vitreous chamber, in eyes after posterior vitrectomy. This therapeutic modality is a good alternative to complete valve removal in patients with progressive corneal damage. In the reviewed study material, tube repositioning was also combined with silicone oil removal from the vitreous chamber.
4. However, in cases where it is not possible to insert the valve tube in the anterior chamber, the modification of the method makes it possible to lower the IOP even in eyes without prior vitrectomy. In cases where the risk of vision loss is caused by persistent failure to control the IOP, a combined procedure with posterior vitrectomy performed prior to Ahmed valve implantation is an alternative modality that brings tangible benefits to patients in compliance with the principle stating that the main focus should be on the final therapeutic outcome.

Valved implants, as the name suggests, help avoid hypotony, which is not uncommon after trabeculectomy procedures or the implantation of non-valved systems.

Case report 8

Female patient, aged 24, monocular. Very large rhegmatogenous retinal detachment, reaching the posterior pole, in the seeing (right) eye with very high myopia (eye length 32 mm). A posterior vitrectomy procedure was performed, and the opacifying lens was removed. Approximately 12 months after silicone oil removal, a progressive increase in the IOP was observed, reaching values of approximately 50 mmHg, and failed to decrease after topical anti-glaucoma treatment. Considering the low risk of hypotony, the Ahmed valve was implanted using the author's modified technique. The patient's IOP (measured by applanation tonometry) on the first day after the procedure was 6 mmHg, and after seven days it was 18 mmHg. No signs of choroidal or retinal detachment were noted during a two-year follow-up period after surgery.

With tight postoperative closure of the conjunctival wound surrounding the valve, the risk of hypotony is very low.

With respect to permanent or progressive complications, it is important to highlight that in the group of patients who originally underwent tube implantation in the vitreous chamber (24 eyes), the two most commonly reported complications (progressive corneal decompensation and conjunctival erosion), were not observed. This shows that the modification made to the procedure improved its efficacy by reducing the number of complications. Most of the described complications were transient.

A persistent, progressive complication is progressive corneal decompensation in the presence of a valve tube in the anterior chamber, causing the tube to migrate into the vitreous chamber.

In more than 34% of cases (14 eyes), the surgery was combined with one to three other ophthalmic procedures. Given their complexity, it is difficult to make comparisons with other authors due to the fact that such complex therapies had not been previously reported.

CONCLUSIONS

Based on 6 years' follow-up of patient outcomes after Ahmed valve implantation, mainly performed with the author's modified technique, for the treatment of refractory glaucoma, it can be concluded that, in the majority of cases, sustained IOP control is achieved in eyes with refractory glaucoma. The procedure is effective and safe both as an isolated treatment to lower the IOP and in combination with other ophthalmic procedures that aim to preserve or even improve useful visual acuity.

The procedure is dedicated to patients with complete and irreversible closure of the natural aqueous outflow pathway through the drainage angle, which is manifested by very high IOP values, exceeding 40–60 mmHg. A key aspect is ensuring that the procedure is done correctly and without delay, before permanent glaucomatous optic nerve damage occurs. Provided that the treatment is initiated in a timely manner, in addition to reducing the IOP, it may help preserve good visual function.

In patients with elevated IOP levels, daily eyeball massage helps to lower the pressure by creating an adequate space around the valve.

Where IOP normalization is unsuccessful, topical medications and additional surgical procedures to lower the IOP are among the available options to maintain the pressure at an appropriate level.

Ahmed valve implantation is one of few reversible procedures available in glaucoma surgery, despite being wrongly considered by many as the 'last-resort' procedure in the treatment of refractory glaucoma.

Valve implantation in the vitreous chamber also contributes to a faster resolution of hemorrhage in the vitreous chamber, which is an additional benefit in eyes undergoing posterior vitrectomy because of ocular complications of diabetes mellitus, which is associated with a higher risk of recurrent intraocular bleeding.

STATEMENT

The author declares no conflict of interest.

References

- Schmidt-Erfurth U, Garcia-Arumi J, Gerendas B, et al. Guidelines for the Management of Retinal Vein Occlusion by the European Society of Retina Specialists (EURETINA). *Ophthalmologica* 2019; 242: 123-162.
- Cywinski A. Causes of failures in the treatment of malignant glaucoma after cataract removal based on an analysis of several case studies. *World Journal of Biology Pharmacy and Health Sciences* 2020; 04: 033-038.
- Alasbali T, Alghamdi AA, Khandekar R. Outcomes of Ahmed valve surgery for refractory glaucoma in Dhahran, Saudi Arabia. *Int J Ophthalmol* 2015; 8: 560-564.
- Riva I, Roberti G, Oddone F, et al. Ahmed glaucoma valve implant: surgical technique and complications. *Clin Ophthalmol* 2017; 11: 357-367.
- Dastiridou AI, Katsanos A, Denis P, et al. Cyclodestructive Procedures in Glaucoma: A Review of Current and Emerging Options. *Adv Ther* 2018; 35: 2103-2127.
- Pandya HK, Tewari A. What is the role of adjunct anti-VEGF therapy in the treatment of neovascular glaucoma (NVG)? *Medscape*, May 19, 2020.
- Takahara Y, Inatani M, Fukushima M, et al. Trabeculectomy with mitomycin C for neovascular glaucoma: prognostic factors for surgical failure. *Am J Ophthalmol* 2009; 147: 912-918.
- Promelle V, Lyons CJ. Long-term Results of Ahmed Valve Implantation With Mitomycin-C in Pediatric Glaucoma. *J Glaucoma* 2021; 30: 596-605.
- Lee CK, Ma KT, Hong YJ, Kim CY. Long-term clinical outcomes of Ahmed valve implantation in patients with refractory glaucoma. *PLoS One* 2017; 12: e0187533.

10. Cywinski A, Bednarski L. A Treatment of Refractory Glaucoma in Pseudophakic Patients after Posterior Vitrectomy using the Ahmed Valve in an Own Modification. *International Journal of Research Studies in Medical and Health Sciences* 2019; 4: 01-05.
11. Bayer A Sci Rep, Ōnol M. Clinical outcomes of Ahmed glaucoma valve in anterior chamber versus ciliary sulcus. *Eye (Lond)* 2017; 31: 608-614.
12. Ramulu PY, Corcoran KJ, Corcoran SL, Robin AL. Utilization of various glaucoma surgeries and procedures in Medicare beneficiaries from 1995 to 2004. *Ophthalmology* 2007; 114: 2265-2270.
13. Kim KN, Lee SB, Lee YH, et al. Changes in corneal endothelial cell density and the cumulative risk of corneal decompensation after Ahmed glaucoma valve implantation. *Br J Ophthalmol* 2016; 100: 933-938.
14. Kim JY, Lee JS, Lee T, et al. Corneal endothelial cell changes and surgical results after Ahmed glaucoma valve implantation: ciliary sulcus versus anterior chamber tube placement. 2021; 11: 12986.
15. Peregrino JIM, Leuenberger EFU, Veloso M. Risk Factors for Conjunctival Tube Erosion in Eyes Implanted with Ahmed ® Glaucoma Valve in a Private Eye Institution in the Philippines. *Philipp J Ophthalmol* 2018; 43: 51-59.
16. Rosentreter A, Lappas A, Widder RA, et al. Conjunctival repair after glaucoma drainage device exposure using collagen-glycosaminoglycane matrices. *BMC Ophthalmol* 2018; 18: 60.