

(01)

Characteristic features of choroidal nevus and small choroidal melanoma in Deep Range Imaging Optical Coherence Tomography

Cechy charakterystyczne guzów wewnątrzgałkowych w Deep Range Imaging optycznej koherentnej tomografii

Anna Markiewicz^{1,2}, Bożena Romanowska-Dixon^{1,2}, Barbara Jakubowska²,
Anna Romanowska-Pawliczek³

¹ Department of Ophthalmology and Ocular Oncology of the Jagiellonian University, Medical College, Cracow, Poland

Head: Professor Bożena Romanowska-Dixon, MD, PhD

² Department of Ophthalmology and Ocular Oncology University Hospital on Cracow, Poland

Head: Professor Bożena Romanowska-Dixon, MD, PhD

³ University of Texas Health Science Center, Houston, United States

Head: Jenifer Juranek, PhD

Abstract:

Purpose: To determine characteristic features of choroidal nevi and small choroidal melanomas in Deep Range Imaging Optical Coherence Tomography in patients diagnosed and treated at the Department of Ophthalmology and Ocular Oncology of the Jagiellonian University, Medical College in Cracow within 2014 year.

Material and methods: 71 patients with choroidal nevi or small choroidal melanomas were studied. Choroidal lesions were diagnosed clinically based on measurements of cross-sectional ultrasound images, mostly B-scans, and color fundus photography. The Topcon's Deep Range Imaging Optical Coherence Tomography was used to enable better visualization of choroidal pathologies.

Results: 11 patients were diagnosed with small choroidal nevus (<1.0 mm thickness and < 3.0 mm diameter), 42 – with typical nevus (1.0–2.0 mm thickness and 3.0–5.0 mm diameter), 5 – with atypical nevus (≤ 2.0 mm thickness and > 5.0 mm diameter) and 13 – with small melanoma (according to Shields' TFSOM rule). Deep Range Imaging Optical Coherence Tomography demonstrated characteristic features of these lesions: compression of choriocapillaris in all atypical nevi and small melanomas, inner and/or outer choroidal changes in all choroidal lesions. Other features, such as subretinal fluid, photoreceptors changes, macrophages with lipofuscin, were mostly present in atypical nevi and small melanomas. Dome tumor shape and wing border shape were found only in small melanomas.

Conclusion: Deep Range Imaging Optical Coherence Tomography enables visualization of all choroidal structures and their pathology. It is useful in differential diagnosis of choroidal nevi and small choroidal melanomas.

Key words:

choroidal nevus, small choroidal melanoma, differential diagnosis, atypical choroidal nevus, Deep Range Imaging Optical Coherence Tomography (DRI-OCT).

Abstrakt:

Cel: przedstawienie charakterystycznych cech znamion naczyńówki i małych czerniaków naczyńówki w Deep Range Imaging optycznej koherentnej tomografii u pacjentów diagnozowanych i leczonych w Klinice Okulistyki i Onkologii Okulistycznej Uniwersytetu Jagiellońskiego Collegium Medicum w Krakowie w 2014 roku.

Materiał i metody: badaniem objęto 71 chorych, u których rozpoznano znamię naczyńówki lub małego czerniaka. Rozpoznanie zmian naczyńówki było potwierdzone podczas obserwacji z wykonaniem pomiarów ultrasonograficznych, przeważnie w prezentacji B, oraz kolorowego zdjęcia dna oka. U wszystkich chorych wykonano badanie Deep Range Imaging optycznej koherentnej tomografii firmy Topcon.

Wyniki: u 11 chorych rozpoznano małe znamię naczyńówki (<1,0 mm wysokości i <3,0 mm średnicy podstawy), u 42 chorych – typowe (1,0–2,0 mm wysokości i 3,0–5,0 mm średnicy podstawy), a u 5 chorych – atypowe (≤ 2,0 mm wysokości i >5,0 mm średnicy podstawy), u 13 chorych zaś małego czerniaka (według reguły TFSOM opracowanej przez Shieldsów). Stwierdzone przez nas charakterystyczne cechy w badaniu Deep Range Imaging optycznej koherentnej tomografii to: kompresja choriokapilar we wszystkich atypowych znamionach i małych czerniakach oraz zmiany w warstwach zewnętrznej i/lub wewnętrznej naczyńówki we wszystkich zmianach. Inne stwierdzone cechy to: plyn podsiatkówkowy, zmiany w warstwie fotoreceptorów i makrofagi obciążone lipofuscyną, które są częściej obecne w atypowych znamionach i małych czerniakach. Zaobserwowano, że kopolasty kształt i skrzydlaste granice guza miały jedynie małe czerniaki.

Wnioski: Badanie Deep Range Imaging optycznej koherentnej tomografii pozwala uwidocznić wszystkie szczegóły budowy naczyńówki i ich nieprawidłowości. Te właściwości są bardzo przydatne w diagnostyce różnicowej znamion i małych czerniaków naczyńówki.

Słowa kluczowe:

znamię naczyńówki, mały czerniak naczyńówki, diagnostyka różnicowa, atypowe znamię naczyńówki, Deep Range Imaging optyczna koherentna tomografia (DRI-OCT).

Introduction

The choroid can be affected by benign and malignant tumors. Benign melanocytic tumors of the choroid, such as choroidal nevi are very common and pose no health risks, unless they show signs of malignancy, in which case they are considered melanomas. Many small choroidal melanomas are located close to optic disc and macula, so any tumor-destructing treatment modality is associated with a high risk of visual loss. However, the watchful waiting approach in potentially malignant lesions can lead to metastases. Therefore, it is crucial to find an effective noninvasive tool for differential diagnosis.

Imaging techniques

Choroidal lesions are diagnosed clinically based on measurements of cross-sectional ultrasound images, mostly A- and B-scans. Color fundus photography is also useful for documentation.

Optical coherence tomography (OCT) has become an excellent, noninvasive imaging technique for evaluation, measurement and observation of retinal and optic nerve disorders. In conventional OCT, light scatter by the retinal pigment epithelium and choroidal vasculature limits and degrades the choroidal images. Enhanced depth imaging optical coherence tomography (EDI-OCT) enables cross sectional retinal imaging with a resolution approaching histologic sections and choroidal mapping. Noori et al. observed that vascular choroidal changes play certain roles in the development of choroidal disorders. In order to effectively detect, evaluate and follow up on choroidal neoplasms, it is important to better establish the use of topographic choroidal thickness and choroidal volume in choroidal lesions and provide a normative database (1–5). Topcon’s DRI-OCT combines color fundus photography with new OCT technology to capture a cross-sectional image of the fundus using light interference. The 3D OCT system enables three-dimensional observation of the fundus by capturing images of both the surface and deeper parts of the retina and choroid.

Purpose

To present characteristic features of choroidal nevus and small choroidal melanoma in Deep Range Imaging Optical Coherence Tomography (DRI-OCT) in patients diagnosed and treated at the Department of Ophthalmology and Ocular Oncology of the Jagiellonian University, Medical College in Cracow.

Material and methods

71 patients with choroidal nevi and small choroidal melanomas were studied. Choroidal lesions were diagnosed clinically based on measurements of cross-sectional ultrasound images, mostly A- and B-scans, and color fundus photography. The Topcon’s Deep Range Imaging Optical Coherence Tomography (DRI-OCT, Topcon, Tokyo, Japan) was used to enable better visualization of choroidal pathologies and their typical features. Two experienced examiners analyzed OCT images.

Results

11 patients were diagnosed with a small choroidal nevus (thickness <1.0 mm and diameter <3.0 mm), 42 – with a typical nevus (1.0–2.0 mm thickness and 3.0–5.0 mm diameter), 5 – with an atypical nevus (thickness ≤ 2.0 mm and diame-

ter >5.0 mm) and 13 – with a small melanoma (according to Shields’ TFSOM rule). DRI-OCT features of melanotic choroidal lesions are presented in Table I. Small choroidal nevus imaged with DRI-OCT displayed compression (thinning) of choriocapillaris (91% of cases), inner/outer segment junction irregularity (82%), choroidal shadowing (91%), flat contour (91%), brush border shape (73%) and whetstone shape (27%) (Fig. 1).

Choroidal nevi presented with compression of choriocapillaris (95% of cases), inner/outer segment junction irregularity (100%), subretinal fluid (10%), retinal pigment epithelium (RPE) changes (28%), photoreceptor loss (31%), inner/outer segment junction irregularity (38%), placid contour (36%), flat contour (55%), whetstone border shape (55%), and brush border shape (41%). The most common DRI-OCT imaging features of both atypical nevi as well as small melanomas were: compression of choriocapillaris (100%), inner/outer segment junction irregularity (100%), RPE changes (100% and 77%, respectively), loss of photoreceptors (100% and 92%, respectively) and wing border shape (60% and 100%, respectively). Only small melanomas had a typical dome shape (Fig. 2).

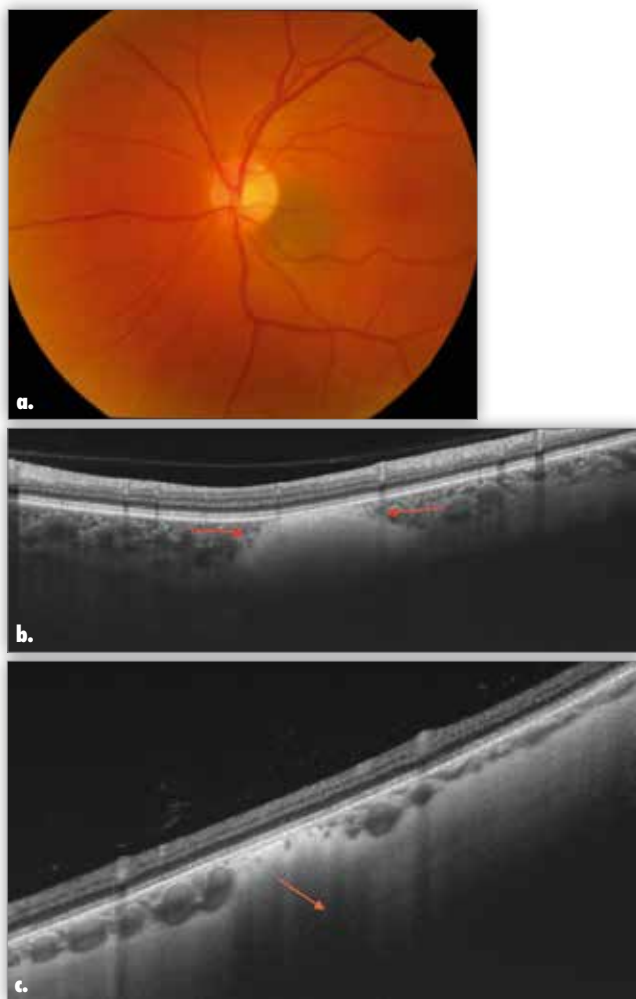


Fig. 1. Choroidal nevus: fundus view – a., and b. – OCT view with characteristic features: compression of choriocapillaris (red arrows), c. – choroid shadowing (orange arrow).

Ryc. 1. Znamię naczyniówki: a. i b. – DRI-OCT z typowymi dla niego cechami – kompresja choriokapilar (czerwone strzałki), c. – cień naczyniówki (pomarańczowa strzałka).

Feature/ Cecha	Small nevus/ Małe znamię (n = 11)	Nevus/ Znamię (n = 42)	Atypical nevus/ Atypowe znamię (n = 5)	Small melanoma/ Mały czerniak (n = 13)
Compression of choriocapillaris / Uciśnięcie choriokapilar	91%	95%	100%	100%
Inner/ Outer Wewnętrzne/ Zewnętrzne	82%	100%	100%	100%
Shadowing/ Zacienienie	91%	100%	100%	100%
Border line/ Linia graniczna	0%	33%	60%	23%
Subretinal fluid/ Płyn podsiatkówkowy	0%	10%	60%	92%
Intraretinal fluid/ Płyn śródsiatkówkowy	0%	5%	20%	54%
RPE changes/ Zmiany RPE	0%	29%	100%	77%
Photoreceptor loss/ Zanik fotoreceptorów	0%	31%	100%	92%
Inner/ Outer photoreceptor segment irregularities/ Nieregularności na granicy segmentów wewnętrznych i zewnętrznych fotoreceptorów	0%	38%	100%	100%
Shaggy/ Frędzlowate	0%	5%	40%	69%
Stalagmites/ Stalagmity	0%	0%	20%	69%
Stalactites/ Stalaktyty	0%	0%	40%	46%
Retracted/ Rozciągnięte	0%	5%	40%	46%
Tips swollen/ Obrzęk fotoreceptorów	0%	14%	80%	69%
Lipofuscin-laden macrophages/ Makrofagi obciążone lipofuscyną	9%	5%	100%	77%
Drusen/ Druzy	0%	5%	0%	15%
Lumpy-bumpy contour/ Powierzchnia zmiany wyboista	0%	2%	0%	0%
Placid contour/ Powierzchnia zmiany gładka	9%	36%	60%	8%
Undulating (rippled) contour/ Powierzchnia zmiany pofalowana	0%	5%	0%	0%
Flat contour/ Powierzchnia zmiany płaska	91%	55%	0%	0%
Regular dome-shaped contour/ Kształt regularnej kopuły	0%	0%	40%	85%
Irregular dome-shaped contour/ Kształt nieregularnej kopuły	0%	0%	0%	8%
Whetstone-shaped lateral border/ Kształt granic bocznych osetka	27%	55%	40%	0%
Wing-shaped lateral border/ Kształt granic bocznych skrzydła	0%	5%	60%	100%
Brush-shaped lateral border/ Kształt granic bocznych pędzel	73%	40%	0%	0%

Tab. I. DRI-OCT features of melanotic choroidal lesions.

Tab. I. Cechy barwnikowych zmian naczyniówki w DRI-OCT.

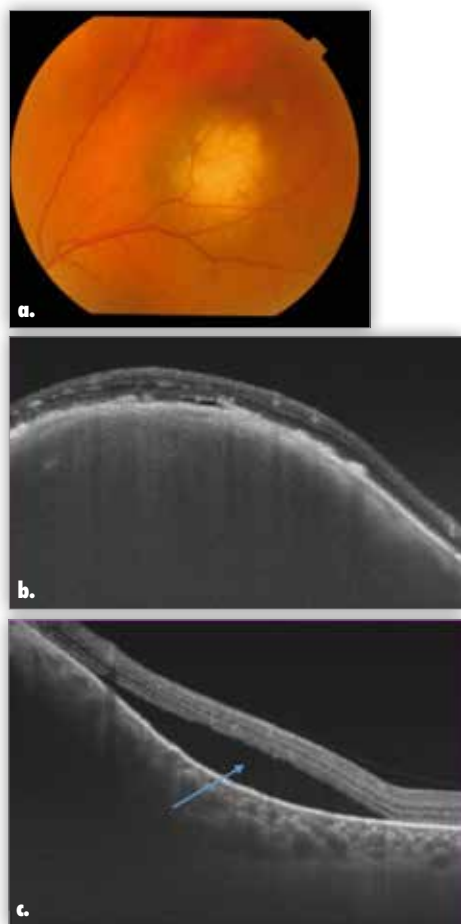


Fig. 2. Small choroidal melanoma: fundus view – a., and b. – OCT view with characteristic features: choriocapillaris compression (technically the absence of choriocapillaris between retina and small melanoma), c. – subretinal fluid (blue arrow).

Ryc. 2. Mały czerniak naczyniówki: a. i b. – DRI-OCT z typowymi dla niego cechami – kompresja choriokapilar (praktycznie brak choriokapilar między siatkówką a małym czerniakiem, c. – płyn podsiatkówkowy (niebieska strzałka).

Discussion

Choroidal nevus is benign lesion. Shah et al. describe common EDI-OCT features of choroidal nevi in 104 patients (2). The most common features included partial (59%) or complete (35%) choroidal shadowing deep to the nevus, thinning of choriocapillaris layer overlying the nevus (94%), RPE atrophy (43%), RPE loss (14%), RPE nodularity (8%), photoreceptor loss (43%), inner segment/outer segment (IS/OS) junction irregularity (37%), IS/OS loss (6%), external limiting membrane irregularity (18%) and subretinal fluid identified overlying the nevus (16%). A comparison of pigmented versus nonpigmented nevus showed significantly more intense choroidal shadowing with pigmented nevus (2).

Shields et al. report gentle contour, choroidal shadowing (94%), compression of choriocapillaris (94%), photoreceptor loss (43%), irregularity of the photoreceptor inner/outer (IS/OS) segment junction (37%) and RPE detachment (8%) as typical of choroidal nevus (2, 3). Subretinal fluid above nevus can sometimes be present. Depending on chronicity of subretinal fluid overlying choroidal nevus, photoreceptors can appear shaggy, chronic with stalactite or chronic with retracted photoreceptors cleft (3).

In our material (71 melanotic choroidal lesions), we observed all discussed features in DRI-OCT (Fig.1). Our findings re-

garding choroidal nevi summarized in Table I are comparable to those listed above. We also noticed different shapes and location (relative to choroidal layer) of nevi. Table I shows differences between small choroidal nevus, choroidal nevus, atypical choroidal nevus and small choroidal melanoma.

Shields et al. examined 37 eyes with small choroidal melanoma with EDI-OCT and compared them with EDI tomograms of choroidal nevi, finding melanoma to be thicker, often with the presence of subretinal fluid and subretinal lipofuscin deposits, and more irregular, including shaggy photoreceptors, which were found in 49% of small choroidal melanomas. Shields et al. postulate that shaggy photoreceptors represent swollen photoreceptors tips or lipofuscin-laden macrophages clinging to the underside of photoreceptors (3, 4). In choroidal melanoma, we also observed compression of choriocapillaris, choroidal shadowing and a relatively common thick layer of subretinal fluid (Fig. 2).

Conclusion

DRI-OCT enables precise visualization of small choroidal lesions, and improves differential diagnosis of choroidal nevus, atypical choroidal nevus and small melanoma. DRI-OCT is a very useful tool in differential diagnosis of choroidal neoplasms. With DRI-OCT, typical features of different choroidal lesions can be found, which helps determine the correct diagnosis.

References:

- Noori J, Riaz Esfahani M, Hajizadeh F, Zaferani MM: *Choroidal mapping: a novel approach for evaluating choroidal thickness and volume*. J Ophthalmic Vis Res. 2012 Apr; 7(2): 180–185.
- Shah SU, Kaliki S, Rojanaporn D, Ferenczy SR, Shields JA: *Enhanced Depth Imaging Optical Coherence Tomography of choroidal nevus in 104 cases*. Ophthalmology. 2012; 119(5): 1006–1072.
- Shields CL: *EDI-OCT of Intraocular Tumors*. Retina Today November/December 2013: 62–65.
- Shields CL, Kaliki S, Rojanaporn D, Ferenczy SR, Shields JA: *Enhanced depth imaging optical coherence tomography of small choroidal melanoma, comparison with choroidal nevus*. Arch Ophthalmol. 2012; 130 (7): 850–856.
- Shields CL, Pellegrini M, Ferenczy SR, Shields JA: *Enhanced depth imaging optical coherence tomography of intraocular tumors: from placid to seasick to rock and rolling topography – the 2013 Francesco Orzalesi Lecture*. Retina. 2014 Aug; 34(8):1495–1512.
- Pellegrini M, Invernizzi A, Giani A, Staurengi G: *Enhanced depth imaging optical coherence tomography features of choroidal osteoma*. Retina. 2014; 34(5): 958–983.

The paper was originally received 22.02.2016 (KO-00055-2016)/ Praca wpłynęła do Redakcji 22.02.2016 r. (KO-00055-2016)
Accepted for publication 26.03.2017/
Zakwalifikowano do druku 26.03.2017 r.

Reprint requests to (Adres do korespondencji):

dr n. med. Anna Markiewicz
Katedra i Klinika Okulistyki i Onkologii Okulistycznej
Wydziału Lekarskiego UJ CM w Krakowie
ul. Kopernika 38
31-501 Kraków
e-mail: annamarkiewicz@interia.pl